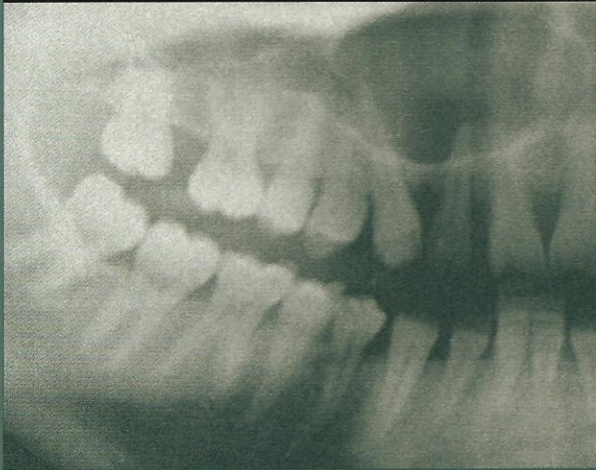


Lasers in Clinical Dentistry

DENTAL CLINICS OF NORTH AMERICA



October 2004

Volume 48

Number 4

theclinics.com

GUEST EDITORS

Donald J. Coluzzi, DDS, and

Robert A. Convissar, DDS

Lasers in aesthetic dentistry

Timothy C. Adams, DDS^a, Peter K. Pang, DDS^{b,*}

^aLas Vegas Institute, 9501 Hillwood Drive, Las Vegas, NV 89134, USA

^bPrivate Practice, 554 Third Street West, Sonoma, CA 95476, USA

Combining the use of lasers with aesthetic dentistry was a mere dream more than 20 years ago. Maiman's [1] invention of the ruby laser over 40 years ago set the stage. In the years following their introduction, there was a steady increase in the use of lasers in medicine. As early as 1963, dermatologists were removing malignant tissue with carbon dioxide (CO₂) lasers, and in 1964 ophthalmologists were using ruby lasers for minor surgery of the eye [2]. According to Myers [3], researchers have looked at a number of possibilities in the electromagnetic spectrum pertaining to lasers. They have found that there are certain wavelengths that are dental specific. By the mid-1990s, the size of the instrument decreased and the ease of use and predictability became more consistent. The cost was reduced dramatically so that today, laser use for aesthetic dentistry is more prevalent.

“Aesthetic” or “cosmetic” dentistry is none other than restorative general dentistry completed to a level that simply makes every attempt to mimic a natural look. The goal is to produce invisible restorations that provide proper form and function to achieve tissue biocompatibility. Of course, gold and mercury amalgam fillings fulfill the functional aspect, but this article necessarily focuses on “tooth-colored” treatments that mimic natural tooth structure. This treatment brings another dimension to restorative dentistry—that of providing nearly invisible restorations. For purposes of clarity, the term *aesthetics* is used in the text; however, in common practice, *cosmetic* and *aesthetic* are interchangeable, as is the optional spelling of *esthetic*.

Often, aesthetic dental procedures are not optional but are necessary and restorative. The patient's concern with short, chipped teeth usually is an occlusal issue that should be addressed and managed with the restorative treatment plan. Another common patient concern is a stained, discolored

* Corresponding author.

E-mail address: DrPang@SonomaCosmeticDentist.com (P.K. Pang).

smile; frequently, the discoloration is due to caries or breakdown of pre-existing restorations. Oral health instruction and dietary counseling should be discussed when appropriate.

Some optional aesthetic dental procedures include bleaching teeth, diastema closures, gummy smiles correction, and modifying teeth severely discolored by tetracycline or fluorosis. In the modern dental practice, laser technology quickly is becoming as useful as the high-speed handpiece, and dental procedures can be accomplished with less invasive methods, a more relaxed appointment, and less postoperative discomfort. Medical surgeons have experienced these benefits with their treatments for decades, and dental providers can accomplish procedures routinely and predictably with laser technology [4].

Two separate issues appear vital for success when performing aesthetic general dentistry. The first is achieving adequate isolation of the operative site, including isolation from moisture contamination. Accomplishing this goal is far easier with gingival health. Because of the inherent nature of tooth decay and its etiology, however, the soft tissue often shows signs of disease (eg, gingival tissue adjacent to a carious lesion can bleed easily). This problem is controlled simply with laser technology by sealing the blood vessels and leaving the healthy tissue intact; the caries removal then can proceed at the same appointment time. Other procedures, when indicated, can be accomplished at the same appointment as the restorative procedure, offering a great advantage to the dentist and the patient [5]. These procedures include laser gingivectomy including crown lengthening, ovate pontic sites creation, uncovering implants and taking impressions, gingival sculpting, and tissue management during bonding procedures.

The second point for cosmetic success is the preservation of as much natural tooth structure as possible, and hard tissue lasers offer this conservation and structural integrity [6]. Supragingival margins facilitate oral hygiene, and the natural colors are more easily mimicked when healthy enamel remains. Traditional G.V. Black preparations no longer are relevant with adhesive dentistry, and unsupported enamel may be bonded and reinforced with resins, as discussed later, enhancing the final result.

The parallels of lasers and aesthetic dentistry are similar when examining their initial concepts and the point in time when their development could be applied clinically with success. This relationship is especially true in the history of bonding to tooth structure. Approximately 40 years ago, investigators discovered etching and bonding to enamel [7–12]. With inadequate materials, polymerization shrinkage, and the inability to successfully bond to dentin, bonding popularity waxed and waned [13,14]. The late 1980s and early 1990s saw improvement in materials and techniques that allowed successful and predictable bonds to not only enamel but also, more important, dentin [15–20]. Despite the earlier developmental failures and pitfalls, bonding and laser use in clinical dentistry became a successful reality in the last 15 years.

Laser instruments

There are essentially five types of lasers currently in the armamentarium for the aesthetic dental practice. This list includes argon, CO₂, diode, erbium, and pulsed Nd:YAG lasers [21].

Argon lasers

These wavelengths emit energy that is absorbed primarily by hemoglobin. This attribute allows for precision cutting, vaporizing, hemostasis, and coagulation of vascular tissue in a contact or noncontact mode [22].

The use of argon in the curing of composite restorations and bonding cements occurs at low power levels (200–500 mW) in the 514-nm range (blue portion of the visible light electromagnetic spectrum) [23,24]. Another application of argon lasers at this wavelength is transillumination of teeth for the purpose of detecting tooth fractures and carious lesions [25].

Carbon dioxide lasers

CO₂ lasers mainly are used for vaporizing, cutting, and coagulation of soft tissue, which includes gross tissue debulking, frenectomies, gingivoplasties, gingivectomies, and biopsies [26]. Due to power and pulsed energy limitations, these lasers are not suitable for cutting bone and tooth structure.

Diode lasers

There are two different wavelengths produced by surgical diode lasers. One uses aluminum-gallium-arsenide to emit approximately 800-nm wavelengths, and the other uses indium-gallium-arsenide to emit 980-nm light energy. These lasers are used in contact mode for rapid cutting, vaporizing, and bacterial reduction of tissue adjacent to tooth structure [27] and used in noncontact mode for deeper coagulation.

Erbium family of lasers

Erbium laser wavelengths are absorbed by collagen, hydroxyapatite, and water components, which allows the lasers to cut soft tissue, tooth structure, and bone.

There are two types of erbium lasers in dentistry today. The erbium:yttrium-aluminum-garnet (Er:YAG) laser produces a wavelength of 2940 nm that allows it to cut teeth easily, quickly, and precisely [28]. The erbium:chromium:yttrium-scandium-gallium-garnet laser operates at a wavelength of 2790 nm and has similar surgical attributes to the Er:YAG. These lasers can be used in contact and noncontact modes. In noncontact mode, the cut is scalpel-like, with very little hemostasis. In the contact mode, there is the ability to perform soft tissue sculpting, with adequate hemostasis [29].

Nd:YAG lasers

Free-running pulsed Nd:YAG lasers in the United States are available only in the 1064-nm wavelength. They have the same use as the diode and argon devices; in addition, there currently are some pulsed Nd:YAG lasers that are cleared by the Food and Drug Administration for the selective removal of first-degree caries, with little interaction to the surrounding healthy enamel [30,31].

Smile design

In this ever-changing world of fast-paced communication, marketing, and shared intelligence, the appearance or looks of someone or something can “make or break” the end result. Whether we peruse on-line, at the bookstore, at our favorite clothing store, or at a new job interview, the way that we look can have a major impact on acceptance and its end result. Plain and simple: whether we buy or do not buy can be directly tied to how something or someone appears. It has been well documented that looking good can enhance social, romantic, and economic consequences and allow an attractive person to get a better job [32]. It now is universally accepted that looking good directly affects an individual’s self-confidence and the image that he or she conveys. Because the face and mouth are the most noticeable parts of the human body, it is no wonder that there is such an increase in demand for smile and teeth makeovers in everyday dental practices [33,34].

Moving from the “mechanical age” to the “adhesive age” in dentistry has forced practitioners to view teeth in an entirely different context [35]. The profession also is seeing a change in the way gingival tissue is handled: with regard to gingival sculpting, it is seeing a move from the “steel (scalpel) age” to the “laser age.” It now is possible, thanks to lasers, to alter gingival tissue conservatively to create a more natural, symmetric, and harmonious appearance. This ability is critical because even with the most incredible-looking restorations, if the gingival tissue is not taken into consideration, then the treatment could be considered an aesthetic failure.

To fully understand the impact that lasers have had on smile design, it is imperative to have a firm grasp on what is to be achieved. The authors have implemented the SMILES evaluation form (Fig. 1) into their private practices to aid them in their goal of incorporating the 10 aspects of an aesthetic smile [36].

SMILES is an acronym that stands for size and golden proportion, *midline* and *canting*, *inclination-axial*, *lip line* versus *incisal edge* of teeth, *extra hard tissue* guidelines, and *soft tissue* conditions. The following are the 10 principles of the SMILES evaluation form:

1. The golden proportion of maxillary anterior teeth (from canine to canine) is determined by using the laterals as a factor of 1. It is known
-

The S.M.I.L.E.S. Evaluation Technique	
Patients Name _____	Date _____
S. - Size and golden proportion.	
Width of centrals _____ Length of Centrals _____ W/L Ratio _____ (75%-80%)	
Golden Proportion _____ / _____ / _____ (1.6/1.1/0.6)	
Centrals Laterals Cuspids	
Correct to proper dimensions if possible	
<input type="checkbox"/> Yes	<input type="checkbox"/> No
M. - Midline and Canting	
Is the midline correct?	Is the smile canted?
<input type="checkbox"/> Yes	<input type="checkbox"/> Yes
<input type="checkbox"/> No how far off _____ R/L	<input type="checkbox"/> No
I. - Axial Inclination	
<input type="checkbox"/> The teeth are properly mesially inclined	
<input type="checkbox"/> Mesial / distal incline which needs correction	
<input type="checkbox"/> Leave teeth as is, even though not properly inclined	
L. - Lip Line vs. Incisal Edge of Teeth	
<input type="checkbox"/> Incisal edges properly follows lip line	
<input type="checkbox"/> Reverse smile line	
<input type="checkbox"/> Deficiency (describe) _____	
E. - Extra hard tissue guidelines	
<input type="checkbox"/> Contact points proper (gingival migration posteriorly)	
<input type="checkbox"/> Gradation of teeth proper	
<input type="checkbox"/> Arch form proper	
Corrections necessary _____	
S. - Soft Tissue Conditions	
<input type="checkbox"/> Good Gingival Symmetry / Correction _____	
<input type="checkbox"/> Good Height and Contour / Correction _____	
<input type="checkbox"/> Gingival Zenith Correct / Correction _____	

Copyright 1995 - Las Vegas Institute for Advanced
 (702) 341-7978 Dental Studies (888) 584-3237

Fig. 1. SMILES evaluation form used for preoperative analysis of aesthetics. (From Dickerson WG. SMILES evaluation form. Las Vegas (NV): Las Vegas Institute for Advanced Dental Studies; 1995; with permission.)

from the literature that the golden numbers are 1.6 to 1.0 to 0.6. Applying the golden numbers to the maxillary anterior dentition makes the central incisors 1.6 × the width of the laterals and the canines 0.6 × the width of the laterals.

- Length and width of the central incisors. The logical starting point for any aesthetic smile is the central incisors. If the central incisors are square or elongated, then their appearance does not reflect proper proportions. This so-called “disproportioned appearance” throws off the rest of the dental arch. The length of the central incisor is divided by the width to obtain an ideal range of 75% to 80%, with <75% being too long and >80% being too short.

3. Midline and arch alignment. The midline should be represented by a vertical line that runs down the center of the face. Even if the nose is not straight, the midline should be centered and straight. The arch alignment should be perpendicular to the midline or parallel with the eyes unless the eyes are canted.
4. Axial inclination. The teeth should have a slight mesial inclination of the vertical axis. This axial inclination is a line drawn from the gingival axis to the center of the incisal edge (or the incisal apex when referring to the canine). The central incisors are the straightest to this axial line, with a gradual mesial inclination as one moves toward the first premolar. From the first premolar distally, the axial inclination stays constant.
5. The lower lip line (versus the incisal edge) calls for the incisal edges of the maxillary teeth to follow the lower lip line, without touching the lower lip in a relaxed position, unless aesthetics or function mandate contact.
6. The interproximal contact points should be close to the incisal edges of the centrals and should gradually move cervically as one moves posteriorly.
7. The gradation of the posterior teeth should be consistent and symmetric as one moves in an anterior-to-posterior direction. This anterior-to-posterior direction should see a gradual reduction in the size of the teeth.
8. When viewing the arch form, drawing a line from canine to canine bisects the incisive papilla in about 92% of the cases.
9. Gingival symmetry. The objective is to create symmetry and contour on both sides of the midline, with regard to the gingival height of the corresponding teeth.
10. Gingival contour and zenith. If one draws an imaginary line from the gingival zenith of the two maxillary canines, one finds that ideally, the canines and centrals are at the same level, with the laterals anywhere from 1 to 2 mm shorter than both the centrals and canines.

Smile design is a personal interpretation that varies slightly geographically. Because there are some differences of opinion among different experts within the framework of the 10 smile design principles, by following this guideline the practitioner is assured success in smile design. Dental lasers easily address the last 2 principles: gingival symmetry and gingival contour.

Biologic width

Bonded all-ceramic restorations have afforded the modern dentist the ability not only to create beautiful, lifelike crowns but also to place the margins of these crowns supragingivally in cases in which the tooth was not previously restored with a subgingival margin. This supragingival placement allows for an aesthetic restoration without the invasion of the periodontal health of the tooth/teeth being restored.

The literature is filled with reports on periodontal health, margin placement, and the stability and health of the dentogingival unit [37–40]. It is the health of the dentogingival complex that is critical to maintain when any type of manipulation of tooth or tissue takes place. Investigators have gone to great lengths to describe this complex [41–45]. In summary, the dentogingival complex extends from the crest of the alveolar bone to the marginal gingival tissue and is composed of a connective tissue attachment, an epithelial attachment, and a sulcular depth. Garguilo [41] reported that the average sulcular depth measurement was 0.69 mm, the junctional epithelial attachment was 0.97 mm, and the connective tissue attachment was 1.07 mm (Fig. 2).

Cohen [42] defined “biologic width” as the sum of the connective tissue attachment and the junctional epithelial attachments, measured from the crest of the alveolar bone to the base of the sulcular crevice. This number came to 2.04 mm when adding the connective tissue attachment measurement of 1.07 mm and the junctional epithelial attachment measurement of 0.97 mm. Kois [44] defined the sum of the connective tissue attachment, the junctional epithelial attachment, and the sulcular depth as the “biologic zone.” This biologic zone would be approximately 3.0 mm, starting at the crest of the alveolar bone and extending to the marginal gingival tissue. To simplify, the biologic width is the sum of the measurements of the connective tissue and junctional epithelial attachments (2.04 mm) and the biologic zone is the sum of the connective tissue and junctional epithelial attachments and the sulcular crevice measurement (2.72 mm). To simplify the biologic zone measurement, Kois [44] suggested a measurement of

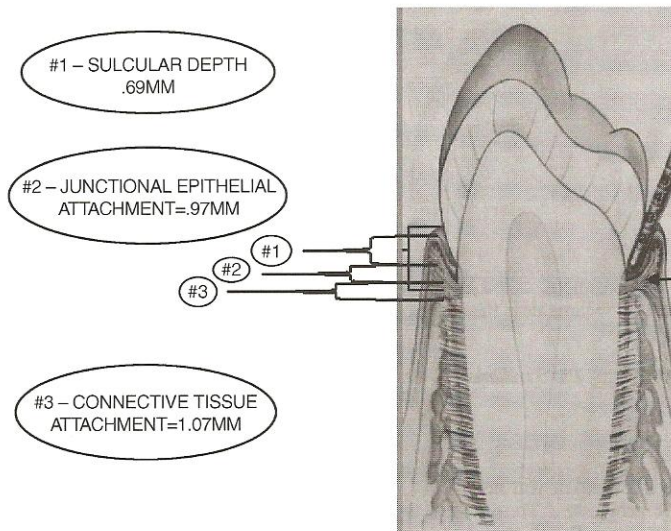


Fig. 2. A picture of the dentogingival complex with average measurements.

3.0 mm to represent a healthy dentogingival complex. This measurement is the minimum required to assure a healthy dentogingival complex (Fig. 3).

Encroachment on the biologic zone or biologic width results in inflammation and periodontal involvement, with the potential for tooth loss due to the loss of the supporting tissue. It is imperative that the clinician respects this important tissue during restorative therapy and tissue manipulation for the best possible aesthetic result.

Case report 1

Examination

The patient was a 24-year-old woman with no medical concerns or history. After examination, it was apparent that the golden proportion of the six upper anterior teeth, the size and length on the centrals, the axial inclinations, the gradation, the gingival symmetry, contour, and zenith were not as aesthetically pleasing as the patient desired. The patient requested aesthetic improvement and wished to have conservative treatment. She wanted better-looking teeth, but could not identify exactly what was bothering her.

The consultation offered a review of the aesthetic principles that realistically could be achieved in a conservative manner. Minimal extension porcelain veneers were discussed as a restorative option, but due to a number of reasons (personal, financial, and occlusal), the treatment plan was finalized to include conservative tissue contouring, with some slight enameloplasty and a frenectomy. The patient gave her informed consent.

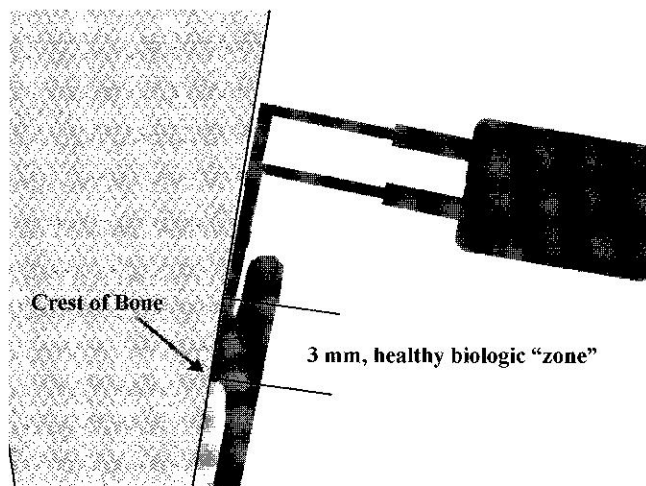


Fig. 3. Graphic depiction of a probe showing the recommended minimum periodontal tissue that must remain to preserve health.

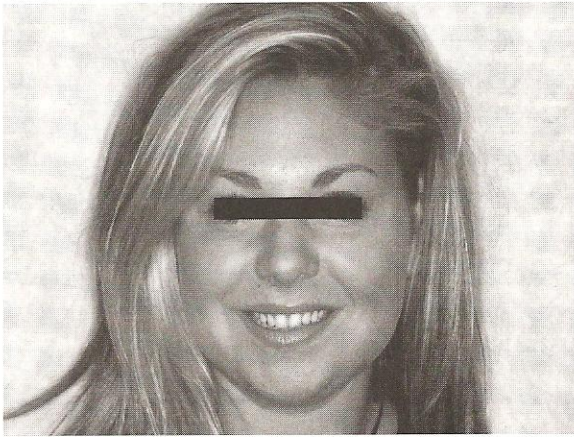

Fig. 4. Preoperative full-face smile view.

Treatment

Polyvinyl siloxane impressions and preoperative digital (Canon Rebel 300 EOS; Canon, Chesapeake, Virginia) pictures were taken for further study (Figs. 4–8).

The patient was anesthetized and pencil marks were made to aid in the determination of proper gingival contour, symmetry, axial inclination, and zenith (Fig. 9). Probing depths were recorded to determine the biologic width and how much tissue could be contoured without involving osseous surgery. Measurements were taken on all teeth, numbers 4 through 13 facially. A periodontal probe was placed apically to the alveolar crest, and the marginal gingival level was measured. These measurements ranged from 4 to 4.5 mm. Remembering that there exists a 3.0-mm biologic zone, the maximum amount of tissue removal could be only 1 to 1.5 mm. Figs. 10–12 show probing to the alveolar crest; the clinician must perform this sounding on each tooth. A diode laser (830 nm; Diodent, Hoya ConBio, Fremont,

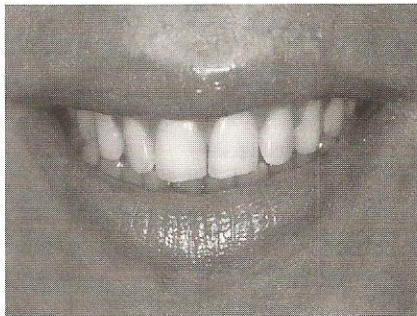


Fig. 5. Preoperative lip smile view.

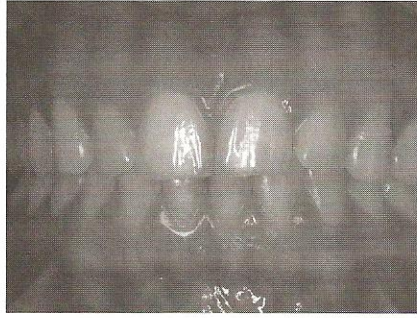

Fig. 6. Preoperative anterior view.

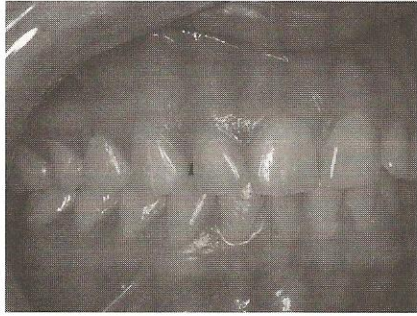

Fig. 7. Preoperative right side view.

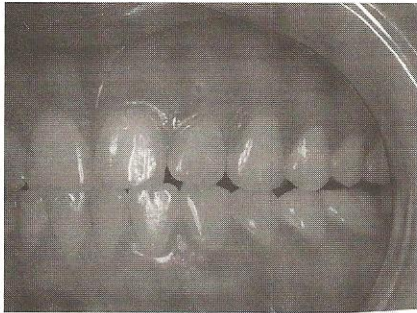


Fig. 8. Preoperative left side view.

California) with a 400- μm initiated fiber and a power setting of 0.8 W continuous wave was used. The laser was active for 15 minutes during the 1-hour appointment. The laser was used to mark reference spots of the biologic zone, allowing the clinician to focus on aesthetics and serving as the visual finishing point (Fig. 13). Proper laser precautions were taken (mask,

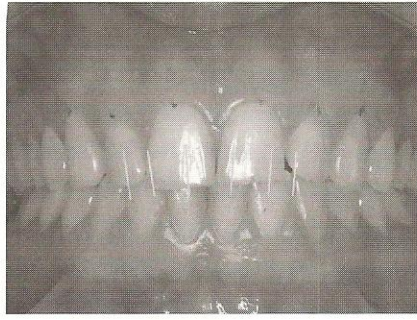


Fig. 9. Pencil marks indicate zenith of tissue.

eyewear, and high-speed suction), and lasing began with the central incisors (Fig. 14). After the ideal symmetry, contour, and zenith were established, the right side was completed, followed by the left side (Figs. 15 and 16). At this time, the author (T.C. Adams) and assistant stood up in front of the patient to view the initial result from a different perspective. A piece of floss was used as a visual guide to determine the gingival contour and symmetry (Fig. 17). Hydrogen peroxide was used to clean up and debride the gingival tissue (Fig. 18). Visual examination revealed that the gingival tissue above the laterals needed to be moved more cervically and that some additional slight contouring on the tissue was necessary above all of the other teeth (Figs. 19 and 20). The incisal enamel was rounded, removing sharp and jagged edges and providing a more feminine appearance (Fig. 21). The treatment plan also included a frenectomy to prevent any pulling of the new location of the marginal gingival (Fig. 22). Fig. 23 shows the pretreatment condition; Fig. 24 shows the immediate postoperative result.

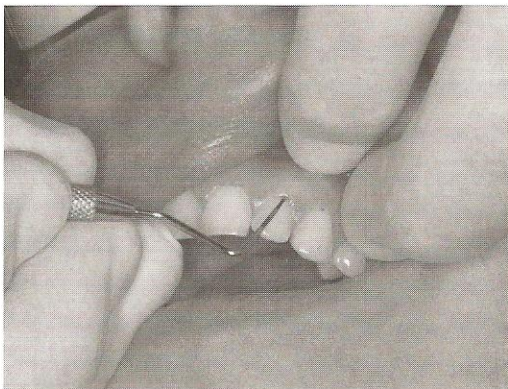

Fig. 10. Probe to the crest of bone, left lateral.

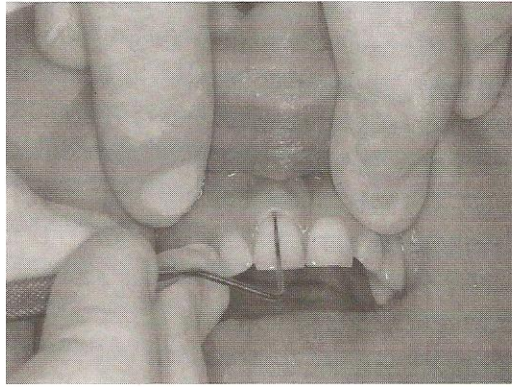

Fig. 11. Probe to crest of bone, right central.

Discussion

The before and after pictures reveal an aesthetic improvement on 6 of the 10 SMILE principles: (the golden proportion of the anterior six teeth, size and length on the centrals, axial inclination, gradation, gingival symmetry, gingival contour and zenith). The diode laser has excellent ability to cut accurately and control hemostasis, yet has poor absorption by tooth structure, thus allowing for the safe cutting in close proximity to tooth structure. The fact that this smile makeover could be achieved conservatively with a laser and some slight tooth structure contouring is very rewarding and satisfying for the patient and the clinician. A 6-day post-operative picture reveals excellent healing, with no complications, and the patient was comfortable throughout the period (Fig. 25).

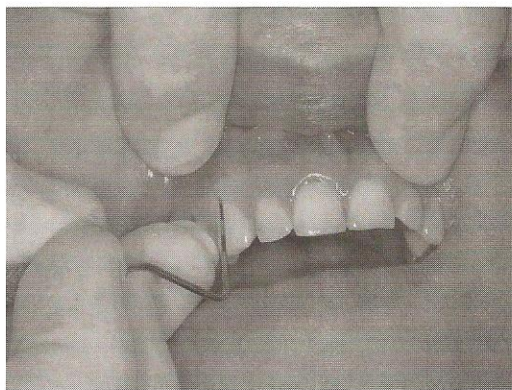


Fig. 12. Probe to crest of bone, right cuspid.

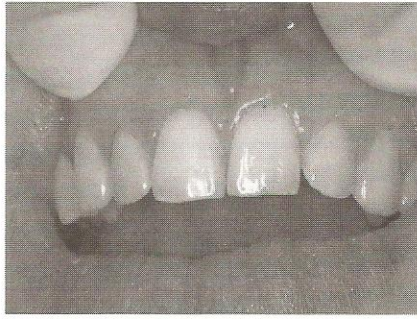


Fig. 13. The diode laser marks finishing points for soft tissue removal.

Case report 2

Examination

A 30-year-old woman who was in excellent health with a known allergy to penicillin presented with the chief concern of discolored front teeth and failing restorations (Figs. 26 and 27).

Treatment plan

The proposed treatment was to replace the failing composites with new direct composite restorations using an erbium laser for tooth preparation. Alternative treatment was porcelain veneer final restorations, not using the laser. The patient chose the direct composites with informed consent.

An Er:YAG laser (2940 nm; OpusDent, Norwood, Massachusetts) was used for the removal of existing discolored resin. A 1000- μ m sapphire tip was attached to the hollow wave guide and the laser was operated at 250 mJ, 15 Hz, and 3.75 W in noncontact mode with a water spray. Total preparation time was 4 minutes (Fig. 28). No anesthetic was required. Laser safety glasses appropriate for this wavelength were used. All caries were removed by tactile exploration and use of caries indicator stain.

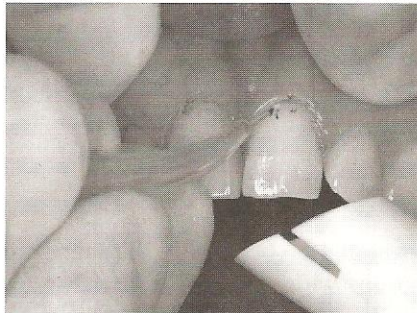

Fig. 14. Diode laser ablation of tissue around centrals.

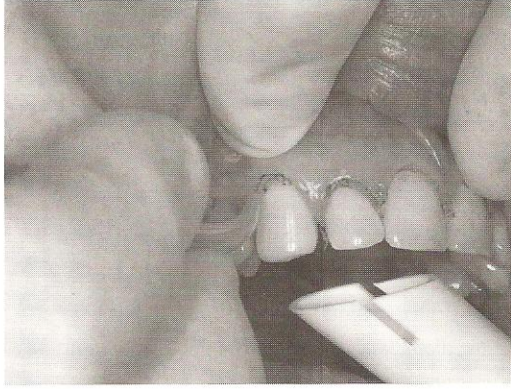


Fig. 15. Laser ablation of tissue on right side.

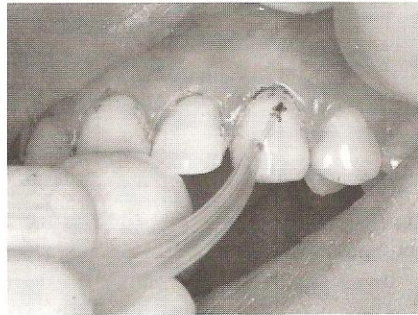

Fig. 16. Laser ablation of tissue on left side.

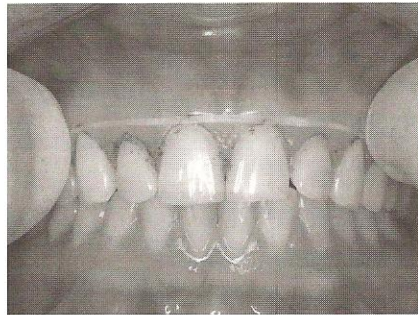


Fig. 17. Dental floss used as guide for height of tissue contour.

Discussion

The 1000- μm tip was chosen because of the shallow depth of penetration. Hard tissue preparations with the erbium laser are technique sensitive. In situations that may require some anesthetic, the author (P.K. Pang) "conditions" or desensitizes the tooth with the laser first. This process can

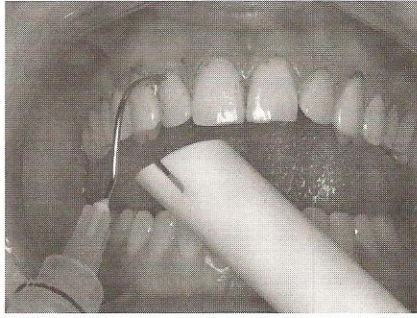


Fig. 18. Hydrogen peroxide irrigation of debris.

be accomplished by using low power and a large noncontact tip in a nonfocused manner. Using a water spray, the author moves the laser beam around the tooth for 2 to 3 minutes. Following this procedure, most treatments can proceed without anesthesia. Fig. 29 shows the postoperative result.

Case report 3

Examination

The patient was a 33-year-old woman in excellent health. Her chief concern was gingival hyperplasia secondary to orthodontic treatment (Fig. 30) and a partially unerupted maxillary second molar (Fig. 31). The treatment plan was a gingivectomy around several anterior teeth and an operculectomy of the molar tissue using diode laser and a cosmetic mock-up smile design to assist the orthodontist in completing the treatment. Periodontal probing was completed, and tissue removal amounts were calculated. Alternative instrumentation of surgical blade and electrosurge were presented, but the patient preferred the laser and provided informed consent.

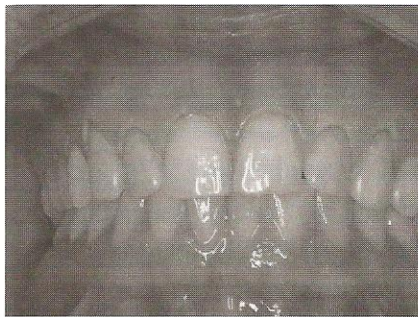


Fig. 19. After irrigation, the tissue contour can be scrutinized. Note that the lateral incisors need more contouring.

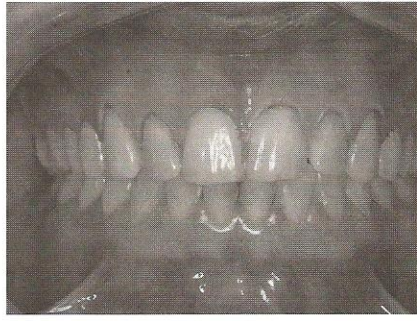

Fig. 20. Gingival contouring completed.

Treatment

The biologic width was determined and marked on the tissue. A diode laser (812 nm; Aurora, Premier Laser Systems, Irvine, California) was used with a 400- μm quartz fiber, initiated contact tip. The power setting of 1.2 W and 30 Hz and a pulse duration of 0.03-seconds was used for a total of 24 minutes on the anterior teeth (Fig. 32). The molar uncovering was treated with a 600- μm fiber, initiated tip in contact mode at 1.6 W continuous wave for 12 minutes (Fig. 33). A topical benzocaine/EMLA mixture was used for anesthesia, and laser safety precautions were followed.

Discussion

The gingival tissue surrounding the molar was much more fibrous and thick, so the larger, 600- μm fiber was chosen. Because this fiber provides a greater spot size, the power required for adequate tissue interaction is greater.

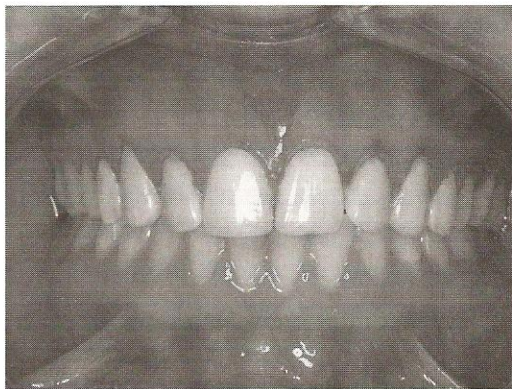

Fig. 21. Incisal edges were contoured with high-speed polishing burs. Note position of the frenum.

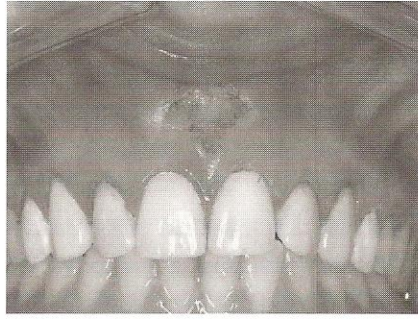


Fig. 22. Frenectomy completed with diode laser.

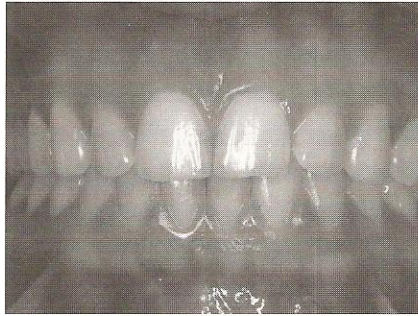


Fig. 23. Preoperative view.

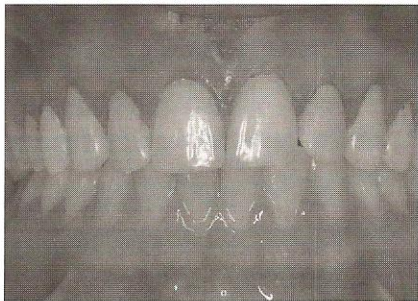

Fig. 24. Immediate postoperative view.

The patient reported no postoperative discomfort and was cautioned not to irritate the sites with brushing. Fig. 34 shows the 24-hour postoperative view of the anterior tissue. Oral hygiene was performed with a cotton-tipped applicator and 3% hydrogen peroxide. With most procedures, normal hygiene practices may be resumed in 4 to 7 days. Further instructions were to avoid hard or crunchy foods for the first 3 days. Possible complications associated with any soft tissue procedure may involve gingival sloughing,

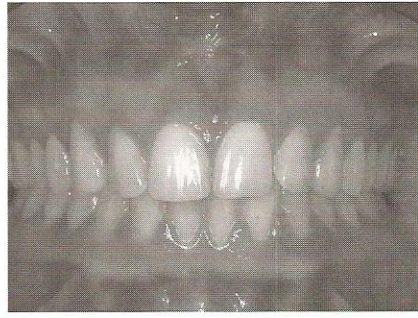

Fig. 25. Six-day postoperative view showing healing and smile improvement.

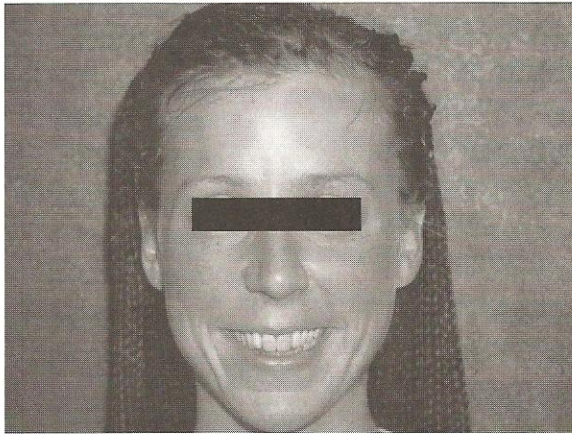


Fig. 26. Smile view of patient.

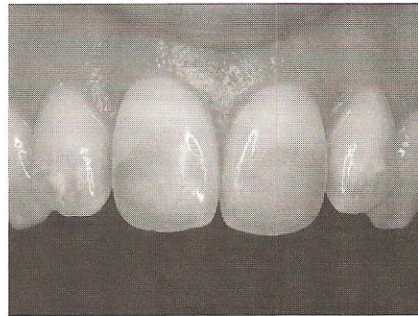

Fig. 27. Close-up of discolored and failing restorations.

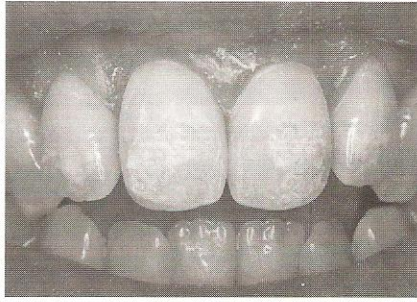


Fig. 28. Teeth prepared with erbium laser.

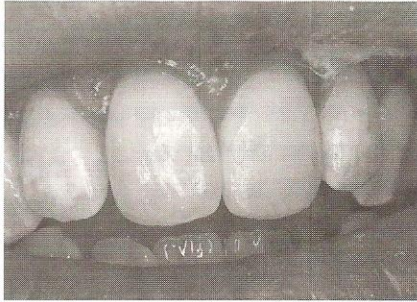


Fig. 29. Immediate postoperative view.

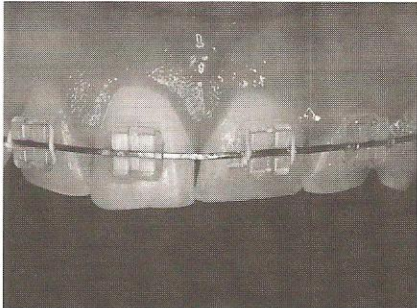


Fig. 30. Preoperative view of anterior teeth and tissue.

uncontrollable bleeding, and moderate-to-severe pain if too much power is used. There were no complications in this case. Figs. 35–39 demonstrate the progress of the healing tissue.

An anterior gingivectomy was accomplished following proper evaluation of smile design principles. This case involved problems with different gingival marginal heights, disparities of the gingival zeniths, and dental inclines. It is important to realize that when aesthetic makeovers are

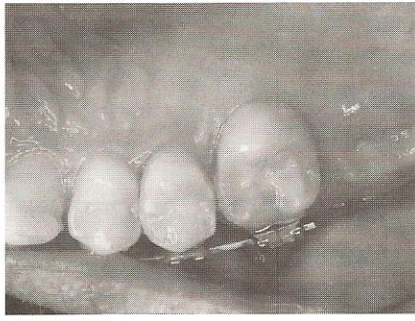


Fig. 31. Preoperative view of molar.

anticipated, the tissue should be altered to follow the proposed final shape of the tooth (Fig. 40). With this case, a prototype mock-up was completed first to aid in visualizing the final smile design. In addition to following the cosmetic smile design principles, the clinician must properly evaluate the biologic width for long-term periodontal stability as previously outlined (Fig. 41).

Case report 4

Examination

The patient was a 30-year-old woman in excellent health undergoing orthodontic treatment. She sought treatment to correct what she visualized as short, wide upper teeth and a gummy smile. Gingival hyperplasia was present in the maxillary anterior area, with frenum impingement (Fig. 42). Preoperative evaluation revealed a 100% length-to-width ratio of the maxillary central incisors. The treatment goal was to provide a ratio of

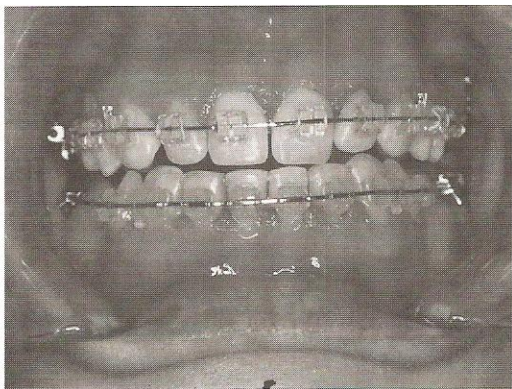


Fig. 32. Diode laser ablation of anterior tissue.

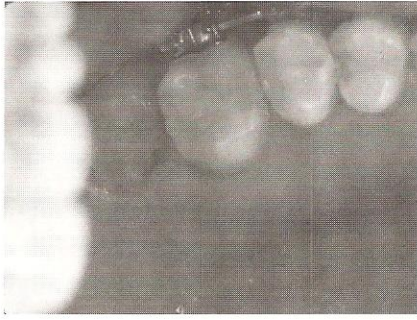

Fig. 33. Diode laser ablation of molar tissue.

75% to 78%. The treatment plan was for a laser gingivectomy using a diode laser on the right side and a CO₂ laser on the patient's left side. Periodontal probing was recorded, and verification of tissue removal dimensions was planned. Alternative modalities that were presented were surgical steel or using only one type of laser. The patient understood that this procedure was for educational purposes and consented to the procedure willingly.

Treatment

Following anesthesia, sounding to bone was accomplished to evaluate adequate biologic width. Two laser wavelengths were used. On the patient's right side, an 830-nm diode laser (OpusDent) was used with a 360- μ m fiber and an initiated tip in contact mode. The power setting was 1.0 W in the pulsed mode of 0.05 seconds on and 0.05 seconds off. These laser parameters were used on teeth nos. 6 through 8 and 25 through 27. The treatment time was 15 minutes.

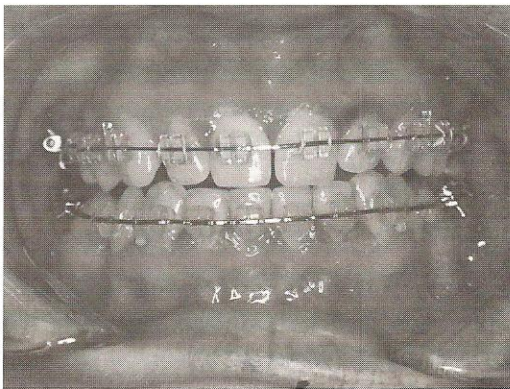

Fig. 34. Twenty-four-hour postoperative view.

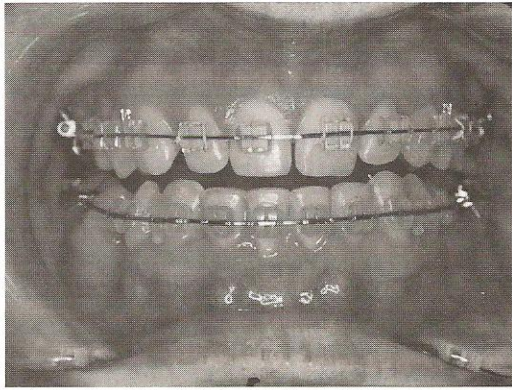


Fig. 35. One-week postoperative view of anterior segment.

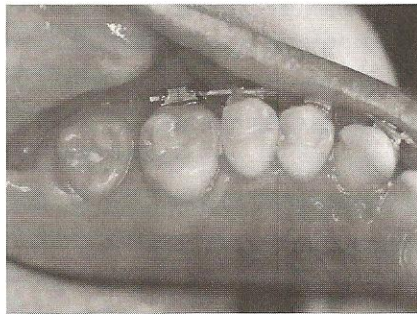


Fig. 36. One-week postoperative view of molar.

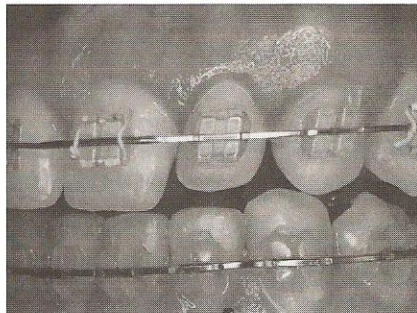


Fig. 37. One-week postoperative view.

On the patient's left side and frenum, a 10,600-nm CO₂ laser (OpusDent) was used with the proprietary "Perioprobe" tip, with 2.0 W continuous wave power used in focused noncontact mode on teeth nos. 9 through 11 and 22 through 24. The enamel surfaces were protected from the laser beam with a metal instrument. The power setting was changed to 2.5 W in

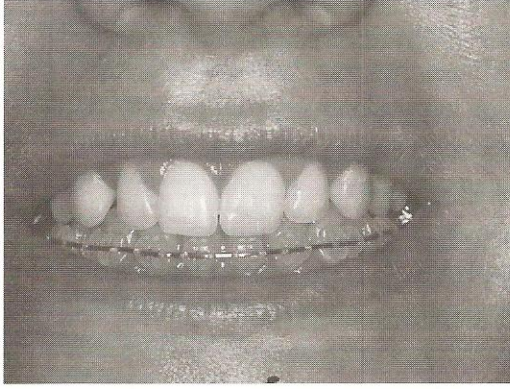


Fig. 38. Six-month postoperative view.

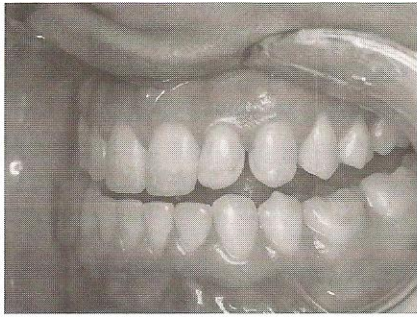

Fig. 39. One-year postoperative view.

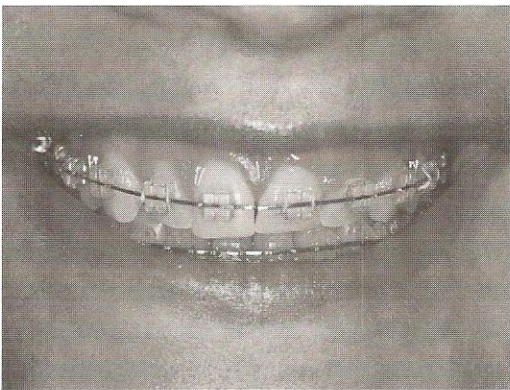


Fig. 40. Preoperative smile.

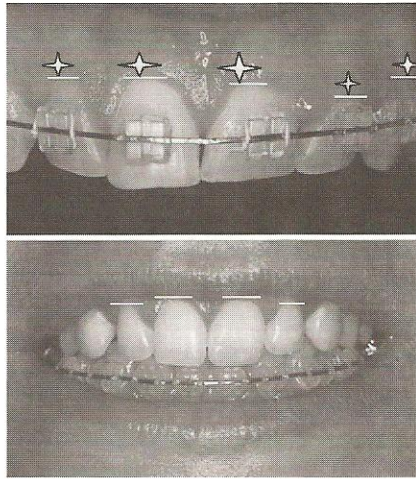


Fig. 41. Smile design evaluation (*top*) and achievement (*bottom*).

a continuous wave, focused, noncontact mode for the maxillary frenum. Final sealing of the left-side surgical site was accomplished with a non-focused tip at 1.0 W, with 100 pulses per second on and 100 pulses per second off. The total treatment time was 20 minutes (Fig. 43).

Anesthesia was provided with 2 Carpules of 4% articaine with 1:100,000 epinephrine. Laser safety measures were used during entire procedure.

Discussion

Postoperative instructions included avoidance of traumatizing the sites with a toothbrush or any hard, crunchy food. The patient was instructed to use a soft cotton applicator and 3% hydrogen peroxide twice daily to gently cleanse the areas. A 1-week evaluation was scheduled and the patient was instructed to call if there were any complications of moderate-to-severe pain, uncontrolled bleeding, or tissue sloughing. The patient reported

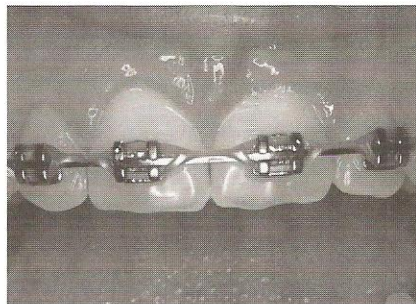


Fig. 42. Preoperative view of gingival tissue and frenum.

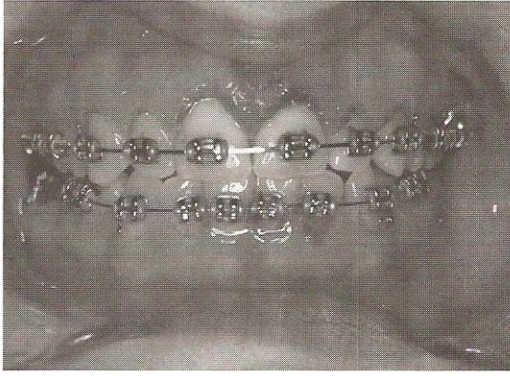


Fig. 43. Diode ablation of tissue on right side and CO₂ laser ablation of tissue on left side and frenum.

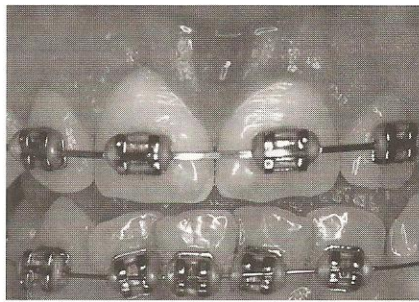


Fig. 44. One-week postoperative view.

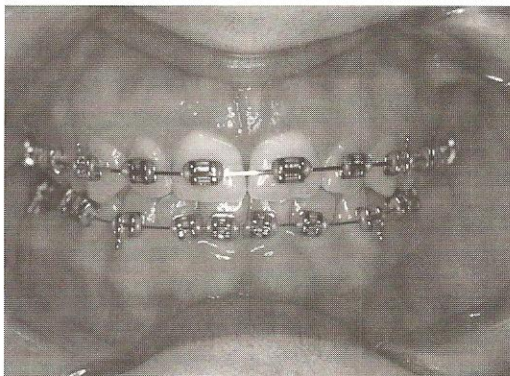


Fig. 45. One-month postoperative view.

minimal-to-no discomfort following the entire procedure. She required only one tablet of acetaminophen the evening of the procedure. In addition, she could not determine any difference between the right and left sides. Clinically, the different tissue interaction can be seen. On the patient's right side, the diode laser left a nearly pristine surgical site with little to no discoloration evident. On the patient's left side, the CO₂ laser left a discolored site; however, the site did not actively bleed like one might expect after a scalpel surgery (Fig. 44). Fig. 45 shows 1-month healing; the aesthetic contour was very pleasing to the patient.

Summary

This article details various laser instruments used in aesthetic procedures. Hard tissue restorations and soft tissue excision and ablation are accomplished easily and accurately by different wavelengths. The principle of maintaining biologic width was demonstrated, and the smile design concept and criteria were shown. When proper form and function is achieved with tissue biocompatibility, the aesthetic procedure is a success; performing the treatment with a dental laser ensures a beneficial result.

References

- [1] Maiman TH. Stimulated optical radiation in ruby. *Nature* 1960;187:493–4.
- [2] Katzir A. Lasers and optical fibers in medicine. Amsterdam: Elsevier Science; 1993.
- [3] Myers TD. The future of lasers in dentistry. *Dent Clin N Am* 2000;44(4):971–80.
- [4] Hall RR. The healing of tissue by a carbon dioxide laser. *Br J Surg* 1971;58:222–5.
- [5] Myers TD. Lasers in dentistry: their application in clinical practice. *J Am Dent Assoc* 1991; 122:46–50.
- [6] Tokoname H, et al. Morphological changes of human teeth with Er:YAG laser irradiation. *J Clin Laser Med Surg* 1999;17(1):7–12.
- [7] Kramer IRH, McLean JW. Alterations in the staining reaction of dentine resulting from a constituent of a new self-polymerizing resin. *Br Dent J* 1952;93:150–3.
- [8] McLean JW, Kramer IRH. A clinical and pathological evaluation of a sulphinic acid activated resin for use in restorative dentistry. *Br Dent J* 1952;93:255–69 [discussion: 291–3].
- [9] Buonocore MG. A simple method of increasing the adhesion of acrylic filling material to enamel surfaces. *J Dent Res* 1955;34:849–53.
- [10] Buonocore M, Quigley M. Bonding of a synthetic resin material to human dentin: preliminary study of the bond area. *J Am Dent Assoc* 1958;57:807–12.
- [11] Buonocore M, Wileman W, Brudevold F. A report on a resin composition capable of bonding to human dentin surfaces. *J Dent Res* 1956;35:846–51.
- [12] Haggar O. Sevitron cavity seal. Swiss patent 278, 946; British patent 687, 299; 1951.
- [13] Feilzer AJ, De Gee AJ, Davidson CL. Measuring contraction of composites and glass ionomer cements. *J Prosthet Dent* 1998;59(3):297–300.
- [14] Roulet JF. The problems associated with substituting composite resin for amalgam: a status report on posterior resins. *J Dent* 1988;16(3):101–13.
- [15] Kanca J III. Resin bonding to wet substrate. 1. Bonding to Dentin. *Quintessence Int* 1992; 23(1):39–41.

- [16] Swift EJ, Triolo PT Jr. Bond strength of Scotchbond Multi-purpose to moist dentin and enamel. *Am J Dent* 1992;5(6):318–20.
- [17] Tam LE, Pilliar RM. Fracture surface characterization of dentin-bonded interfacial fracture toughness specimens. *J Dent Res* 1994;73(3):607–19.
- [18] Jackson R. A technique for placing multiple esthetic inlays and onlays. *Compend Contin Educ Dent* 1996;17(10):918–24.
- [19] Dickerson WG. Indirect resin restorations, the proper technique to ensure success. *Compend Contin Educ Dent* 1993;14(2):216–24.
- [20] Jackson RD. Indirect resin inlay and onlay restorations: a comprehensive clinical overview. *Pract Periodont Aesthet Dent* 1999;11(8):891–900.
- [21] Manni JG. Dental applications of advanced lasers. Burlington (MA): JGM Associates; 2003.
- [22] Powell GL, Blankenau RJ. The use of the argon laser for soft tissue procedures. *J Oral Laser Applic* 2002;2:235–7.
- [23] Fleming MG, Maillet WA. Photopolymerization of composite resin using the argon laser. *J Can Dent Assoc* 1999;65:447–50.
- [24] Powell GL, Blankenau RJ. Laser curing of dental materials. *Dent Clin N Am* 2000;44(4):923–30.
- [25] Kutsch VK. Dental caries illumination with the argon laser. *J Clin Laser Med Surg* 1993;11:323–7.
- [26] Israel M. Use of the CO₂ laser in soft tissue and periodontal surgery. *Pract Periodont Aesthet Dent* 1994;6(6):57–64.
- [27] Moritz A, Gutknecht N, Doertbudak O, Goharkhay K, Schoop U, Schauer P, et al. Bacterial reduction in periodontal pockets through irradiation with a diode laser. *J Clin Laser Med Surg* 1997;15(1):33–7.
- [28] Fife CG, et al. Preparation time and pulpal temperature effects of Er:YAG laser treatment. *J Dent Res* 1998;77(Special issue A):284 [abstract 1428].
- [29] Puricelli E, et al. Oral soft tissue surgery using Er:YAG laser in contact and non-contact modes. 7th International Congress of Lasers in Dentistry. Brussels, Belgium, International Society for Lasers in Dentistry; 2000. Abstract 29.
- [30] White JM, Goodis HE, Rose CL. Use of the pulsed Nd:YAG laser for intraoral soft tissue surgery. *Lasers Surg Med* 1991;11(5):455–61.
- [31] White JM, Goodis HE, Setcos JC, Eakle S, Hulscher BE, Rose CL. Effects of pulsed Nd:YAG laser energy on human teeth: a three year follow-up study. *J Am Dent Assoc* 1993;124:45–50.
- [32] Goleman D, Goleman TB. Beauty's hidden equation. *Am Health* 1987.
- [33] Patzer GL. The physical attractiveness phenomena. New York: Plenum Publishing; 1985.
- [34] Lombardi RE. The principles of visual perception and their clinical application to denture esthetics. *J Prosthet Dent* 1973;29:358–82.
- [35] Degrange M, Roulet JF. Minimally invasive restorations with bonding. Chicago (IL): Quintessence Publishing; 1997.
- [36] Dickerson WG. SMILES evaluation form. Las Vegas (NV): Las Vegas Institute for Advanced Dental Studies; 1995.
- [37] Waerhaug J. Histologic considerations which govern where margins of restorations should be located in relation to the gingival. *Dent Clin N Am* 1960;5:161–76.
- [38] Stein RS, Glickman I. Prosthetic considerations essential for gingival health. *Dent Clin N Am* 1960;4:177–88.
- [39] Newcomb JG. The relationship between the location of subgingival crown margins and gingival inflammation. *J Periodontol* 1974;45:151–4.
- [40] Harrison JD. Crown and bridge preparation design and use. *Dent Clin N Am* 1996;10:185–93.
- [41] Garguilo AW, Wentz FM, Orban B. Dimensions of the dentogingival junction in humans. *J Periodontol* 1961;32:261–7.

- [42] Cohen DW. Periodontal preparation of the mouth for restorative dentistry. Paper presented at the Walter Reed Army Medical Center, Washington, DC. 1962.
- [43] Ingber JS, Rose LF, Coslet JG. The “biologic width”—a concept in periodontics and restorative dentistry. *Alpha Omegan* 1977;70(3):62–5.
- [44] Kois JC. New paradigms for anterior tooth preparation: rationale and technique. *Contemp Esth Dent* 1996;2:1–8.
- [45] Vacek JS, Gher ME, Assad DA, Richardson AC, Giambarresi LI. The dimensions of the human dentogingival junction. *Int J Periodont Rest Dent* 1994;14(2):154–65.