A Contemporary Approach to Bread and Butter Posterior Restorations: A CASE STUDY

BY TIMOTHY C. ADAMS, DDS, LVIM

Aesthetic, Cosmetic, Smile Rejuvenation, Adhesive Dentistry, Smile Makeovers – they are the emphasis and catch phrases in dental practices in North America today.

Due to an increase in awareness brought on by marketing, a more educated public and an increase in post-graduate dental training, these catch phrases have driven the focus of dentistry in North America today. The influx of a vast array of excellent materials, an increased knowledge and improvements in technology have raised the bar of expectations associated with what we deliver to our patients in the anterior region of the mouth. What is missing to a degree, in this author's opinion, is the notion that we can fabricate and deliver the same beautiful and functional aesthetic restorations in the posterior region of the mouth that we do in the anterior region of the mouth. Posterior restorations are the bread and butter of real life practices and to be able to consistently deliver excellent fitting, functional and aesthetic restorations can and should be very rewarding. It is essential that for the aesthetic posterior restoration to come to fruition, an open communication with your lab

What is missing to a degree, in this author's

is critical. Without the proper communication with your lab concerning the proper case selection from an occlusion standpoint, proper materials, shade selection and color mapping and photography, the end result will be very average at best. The following is a case study of a quadrant of Empress restorations emphasizing the importance of lab communication.

opinion, is the notion that we can fabricate and deliver the same beautiful and functional aesthetic restorations in the posterior region of the mouth that we do in the anterior region of the mouth.

CASE STUDY

A patient presented herself with the desire to replace her existing alloys in teeth numbers 2,3 and 4 with the strongest, most conservative aesthetic restorations that were clinically possible. The patient was experiencing no sensitivity and her oral hygiene was impeccable. After discussing the options with her, it was mutually agreed upon that we would plan on utilizing Empress inlay/onlays to restore these three teeth close to, if not equal to their original strength. The advantages of adhesive dentistry in the posterior have been well documented in the literature for years. There have been some experts that have felt that bonded adhesive porcelain restorations rival gold in their longevity (Roulet: Minimally Invasive Restorations With Bonding, Quintessence Books, 1997, page 21).

With this in mind and upon the patients approval, pre-operative photographs were taken of teeth numbers 2,3 and 4 (Figure 1). Shades were also taken at this time and again at the final prep. This allows for comparison of the shade of the tooth structure with and without the alloys, which can cause a graying effect on the actual tooth structure. A rubber dam was placed (Figure 2) and the alloys were conservatively removed using copious water and high speed suction. Once the alloys were removed, the existing recurrent decay that existed in all three teeth was carefully removed. A slight pin hole exposure was noted on the mesial buccal pulp horn of tooth number 3 (Figure 3). The exposure was disinfected with Consepsis (Ultradent), rinsed with water and acid etched with phosphoric acid (Ultradent), rinsed again and lightly dried. The exposure was then saturated with Super Seal (Phoenix Dental) and the excess rewetting agent was blotted off by a microbrush (Kerr). Two layers of Optibond Solo Plus (Kerr) were then carefully applied and with the use of a multibrush, being careful not to get excess over the remaining exposed dentin. After removing the excess primer with a multibrush, the

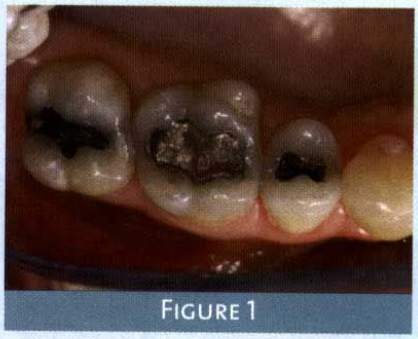
FIGURE 1

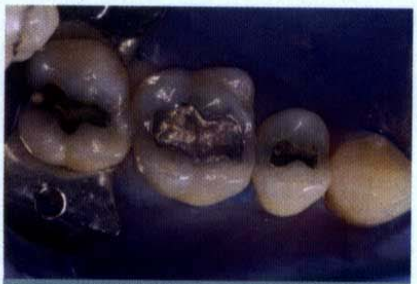
FIGURE 2

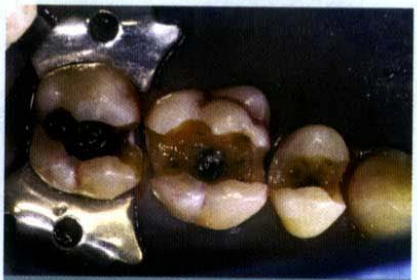
FIGURE 3

---

primer was lightly air thinned to dissipate any excess monomer left on the tooth surface. A thin layer of flowable resin (A-1 Revolution, Kerr) was then applied and both primer and flowable resin were

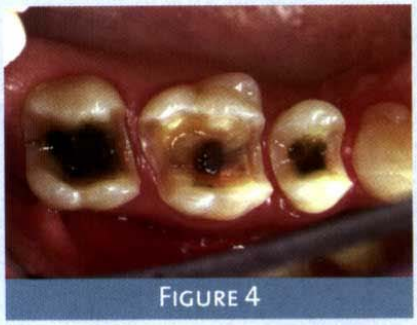

FIGURE 4

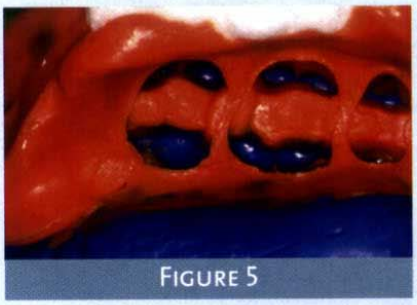

FIGURE 5

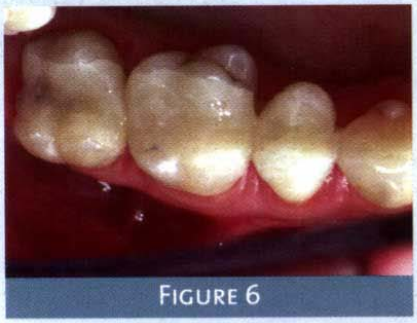

FIGURE 6

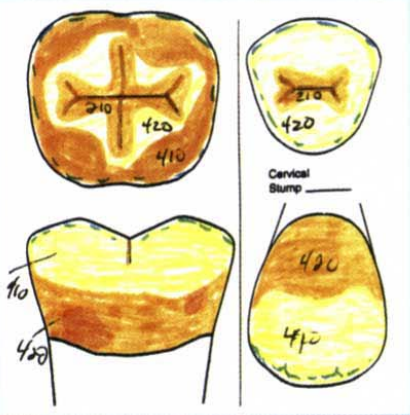

FIGURE 7

light cured for 20 seconds. At this time, the rubber dam was removed and careful examination of the existing tooth structure and occlusion revealed enough solid tooth structure to consider inlays/onlays versus full coverage crowns on all three teeth (Figure 4).

A polyvinyl Siloxane impression (Kerr Take One) was then taken with a full arch tray. Good detail with no bubbles, blood, saliva or distortion was evident (Figure 5). A pre-operative Polyvinyl Siloxane impression (Kerr, Monophase) was then used to fabricate the temporaries. To eliminate the possibility of the temporary material adhering to the pulp cap, a thin layer of Deox (Ultradent) was placed over the pulp cap after the teeth were saturated with a desensitizing agent Super Seal (Phoenix Dental), dried and saturated with an antibacterial agent, Consepsis (Ultradent) and dried again. This prevents the temporary material from bonding to the pulp cap. The temporary material (Integrity A-1, Kerr) was placed into the pre-operative monophase impression and placed over the prepared teeth for two and one-half minutes, then carefully removed. Due to the fact that we used a Polyvinyl Siloxane impression for accuracy, there was little excess of temporary material that needed to be cleaned up. An Enhance cup (Dentsply Caulk) was then used with water spray to lightly clean up any excess. The occlusion was checked and the patient was dismissed with the proper post-operative instructions, especially with the inherent concerns that the pulp cap might develop into an endodontic situation (Figure 6). Color mapping was then performed using the LVI color mapping tablets (LVI) (Figure 7).

> *The color mapping step along with photographs is critical to send to the lab to ensure that the lab has all of the tools needed to produce an exact duplication of the natural teeth. It has been my experience that this step has been the missing piece of the puzzle that keeps clinicians from delivering posterior restorations that rival their anterior restorations aesthetically.*

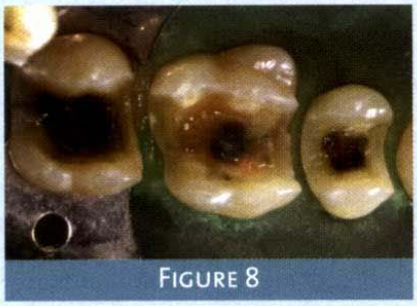

FIGURE 8

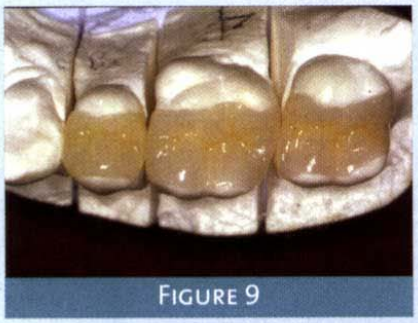

FIGURE 9

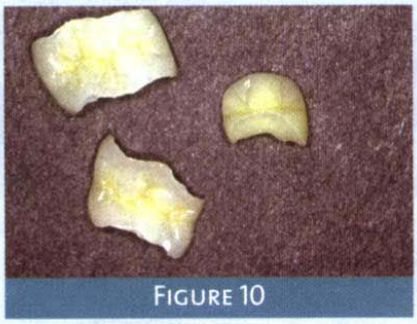

FIGURE 10

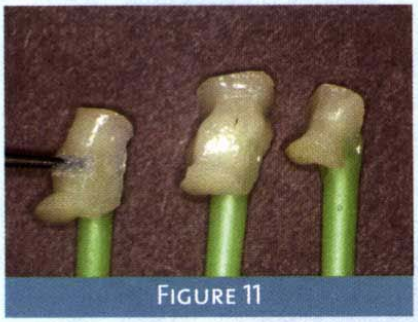

FIGURE 11

The color mapping step along with photographs is critical to send to the lab to ensure that the lab has all of the tools needed to produce an exact duplication of the natural teeth. It has been my experience that this step has been the missing piece of the puzzle that keeps clinicians from delivering posterior restorations that rival their anterior restorations aesthetically. I used both the Mosaic and Chromoscope Shade guides to communicate to the lab the shades, opacity, hypocalcification and translucency desired to replicate the existing natural tooth structure. Please note that it is highly unusual to have a tooth that is just one shade with no opacity, hypocalcification and translucency. These have to be built into the teeth and if this is not communicated to the lab, then your end result will not look natural nor will it blend into the remaining tooth structure.

Two weeks later, the patient returned for the delivery of her three Empress (Ivoclar) restorations. She experienced no discomfort in her temporaries and was excited to get her three new restorations. The patient was properly anesthetized and the temporaries were removed (Figure 8). The prepped teeth were cleaned with hydrogen peroxide (Ultradent) and disinfected with Consepsis (Ultradent). Upon examination, the restorations (Figures 9,10) were an exact match of the color mapping that was provided to the lab along with the pictures that were sent along with the case (Figures 1,2,3,4,5). The restorations were tried in and it was determined that the fit, margins, contour and contacts were excellent. A light yellow try in paste (VarioLink II, Ivoclar) was selected to give the restorations a good blend and warmth. The restorations were removed from the teeth and rinsed with water and dried. Phosphoric acid (Ultradent) was then applied on the internal aspect of the restorations to acidify the surface and rinsed with water and dried. A coating of Kerr Silane Primer (Kerr) was then applied to the internal aspect of the restorations and allowed to air dry. A shiny surface should be noted on the internal aspect of the restorations (Figure 11). Kerr Silane Primer Plus allows you to silanate and coat the restoration with an unfilled resin all in one application.

With the restorations ready to be bonded into place, a rubber dam was placed and the teeth were disinfected again with Consepsis (Ultradent) and rinsed and lightly dried. The teeth were then etched – the enamel first for 15 seconds and then the dentin for 10 seconds and rinsed with a copious supply of water and lightly air dried. The teeth were then saturated with Super Seal (Phoenix Dental) for a minimum of 30 seconds to allow for proper rewet-

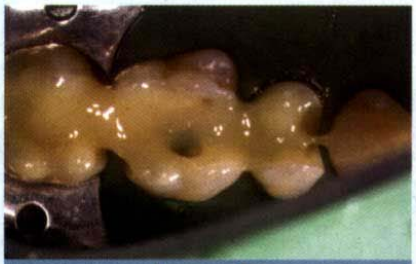

FIGURE 12

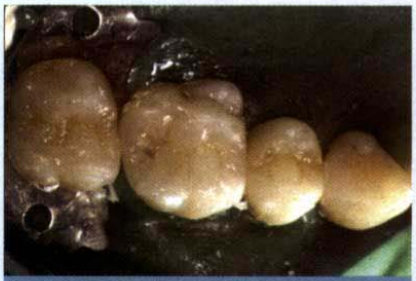

FIGURE 13

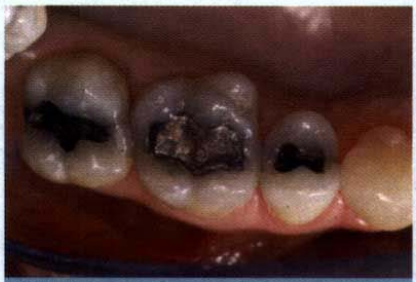

FIGURE 14

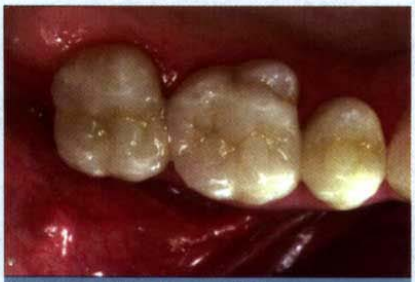

FIGURE 15

> *Before the primer is cured, care should be taken to make sure there is no pooling of the primer that would create too thick of a layer of primer. This could possibly impede the seating of the final restorations.*

ting of the dentinal tubules. The excess was blotted off with a Microbrush (Kerr) giving the teeth a glistening surface that is now ready to be primed. Two coats of Optibond Solo Plus (Kerr) was then applied generously and lightly air thinned. Before the primer is cured, care should be taken to make sure there is no pooling of the primer that would create too thick of a layer of primer. This could possibly impede the seating of the final restorations. After air thinning the primer, the author uses a Microbrush to remove any pooled primer. The primer is then light cured and the teeth are ready for the insertion of the final restorations. The prepped teeth are then filled with the resin cement (Variolink, Ivoclar, Light Yellow, base light cured only) (Figure 12) and the three restorations are then placed into the corresponding prepped teeth making sure not to place too much seating pressure. If firm pressure is used at this point before you are ready to spot tack the restorations into place, they could possibly drift up due to hydraulic pressure causing a suck back affect and consequently microleakage could occur. Once the restorations are ready to be spot tacked and the excess resin cement is cleaned up with a multibrush and a rubber tip (Butler), firm pressure can be placed and the restorations can now be spot tacked into place for 3 seconds on both the buccal and lingual surfaces. The restorations are then flossed and immediately final cured for 20 seconds on the buccal, lingual and occlusal surfaces. Excess resin cement is then removed using a scaler and the rubber dam is ready to be removed (Figure 13). The occlusion is checked and adjusted with a fine diamond and then a carbide bur, being careful not to remove centric stops. The final clean-up and polish is performed using porcelain polishing cups and points and diamond polishing paste (Brasseler). The before and final Empress restorations reveal an excellent fit and color match. (Figure 14, 15).

The desire to consistently deliver fantastic looking and fitting restorations in the posterior portion of the mouth is certainly in the realm of possibility. If we, as clinicians, spend the time to color map, photograph and communicate beautiful looking anterior restorations to our lab, why is it not possible to deliver the same beautiful restorations in the posterior portion of the mouth? Just because our patients might not see them as well doesn't mean that we don't see them on those 6-month recalls. There is nothing more rewarding than to see these restorations come back every 6 months and your hygienist exclaims, "I can't even tell which ones they are". Without the proper tools for communication with your lab these restorations just won't happen.

The desire to consistently deliver fantastic looking and fitting restorations in the posterior portion of the mouth is certainly in the realm of possibility.

Dr. Timothy C. Adams is a Clinical Director at LVI. He is a graduate of Indiana University School of Dentistry where he taught clinical dentistry for 5 years. He maintained a highly successful, full-time, private practice emphasizing aesthetic-restorative dentistry for 17 years. He followed his dream of teaching and moved to Las Vegas to join the full-time LVI faculty. An enthusiastic lecturer, instructor and author of many articles on the latest aesthetic-restorative procedures, Tim is part of the LVI Faculty practice.