

# The Anterior Single Tooth Aesthetic Challenge

BY TIMOTHY C. ADAMS, DDS, LVIM

*The aesthetic restoration of a straight-forward 6-unit to full arch combination veneer/crown/bridge case to a full mouth rehabilitation case presents the clinician with a number of challenges to overcome. When designing a checklist to manage these cases the astute clinician must take into account:*

- Smile Design
- Prep Design
- Color Mapping
- Proper photography for personal and lab communication and co-diagnosis with the patient as to what shape, size and color the patient desires,
- Golden Proportions
- Bite Management

a. *Capturing (if it is determined that a new bite is needed and has been adequately managed and stabilized in plastic via an orthosis)*

*b. Managing (whether it is a new bite or the existing CO bite measured in 6 dimensions-anterior and right and left posterior vertical measurements as the case is prepped and temporized)*
*c. Finishing the bite via the science and art of coronoplasty in 6 dimensions*
*d. What type of restorative material and how it will be cemented or bonded into place must also factor into the equation*

To properly sequence these aesthetic cases obviously takes an immense amount of planning and communication with the dental TEAM, the patient and the lab. One omission from the above checklist can result in a failure, and hours of wasted frustration to rectify the omission, not to mention the monetary loss for both you and your patient.

It would appear that with only one tooth to restore the task becomes dramatically less challenging. The checklist becomes less daunting due to the fact that there is only one tooth to restore. Unfortunately this is exactly the opposite of what we find. The truth is that the anterior single tooth is probably the biggest aesthetic challenge that we face in dentistry today. Why? Because the aesthetic dentist can control the shape and color of the restorations when doing a 6-unit to full arch combination veneer/crown/bridge restorative case. When restoring only one tooth in the anterior segment of the mouth, the shape, size and color will be more or less dictated by the adjacent teeth. In addition there is the question of how the color is perceived by the dentist, patient and the lab technician.

What we know from our basic understanding of color is that we really don't see color or objects. What we really see are wavelengths from the visible electromagnetic spectrum (approximately 400 – 800 nm). It is the absorption and reflection of the wavelengths off of an object that allows us to process color. The object, absorbs and reflects wavelengths and it is the reflected wavelengths that are absorbed by the eye. The light is then changed to electrochemical signals that are sent to and interpreted by the brain as colored objects. In summary, light interacts with an object (absorbed and reflected wavelengths) which sends electrochemical signals to be interpreted by the brain. If there was no light there would be no wavelengths to be absorbed by the eye and processed by the brain as color. Without an object to allow light to absorb or reflect would give us white light only. Without a person to view this reflection of wavelengths off of an object, there would be no perception of color. What this does to the aesthetic dentist is really complicate the process of color matching. As one can see, color is an interpretation of electchemical signals by the brain. This means that we all interpret color with variation. There is a perceptional variation between the dentist, patient and lab. In addition to this difficulty, metamerism

***What we know from our basic understanding of color is that we really don't see color or objects.***

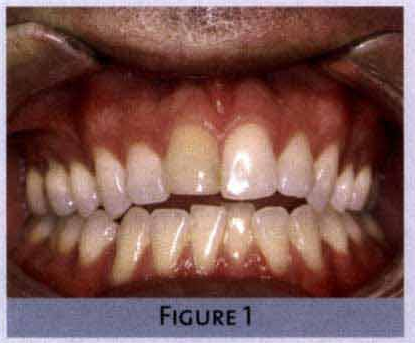

FIGURE 1

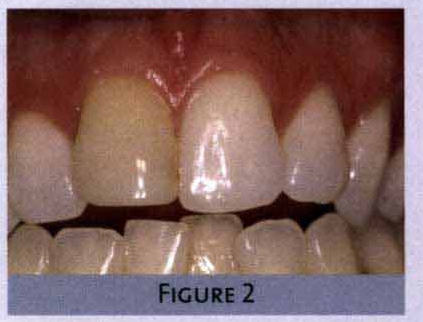

FIGURE 2

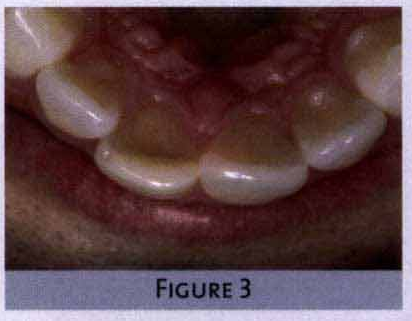

FIGURE 3

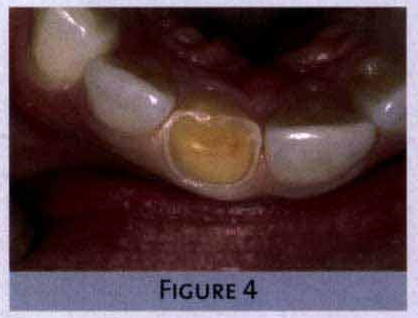

FIGURE 4

needs to be taken into consideration. Metamerism is when an object (ie. veneer, tooth) is viewed differently under different lighting sources. For example the same veneer might appear different under incandescent lighting in your office as compared to color corrected lighting (5500K) at your lab. So do your dental operatories have the same lighting as your lab?

It is difficult enough to achieve the right shape and size, but to now satisfy color demands and be on the same wavelength as your patient and lab makes this all the more challenging. It is no wonder that the anterior single tooth restoration is not even attempted by some. With this in mind, the following case report will attempt to satisfy all of these challenges that present to the clinician when attempting to restore an anterior single tooth restoration. It is important to note that a thorough and realistic conversation with the patient concerning realistic expectations is imperative. As noted in the above paragraphs, there are many steps and possibilities for breakdown due to the "triad of perception" (dentist, patient and lab). A 100% perfect color match is not always realistic and this challenge should be conveyed to the patient. It is perfectly acceptable to always strive for 100% perfection, but in the real world of dentistry, realism prevails. When you strive for perfection every time you get closer to the perfect end result, but buffer it with realism.

> *It is difficult enough to achieve the right shape and size, but to now satisfy color demands and be on the same wavelength as your patient and lab makes this all the more challenging. It is no wonder that the anterior single tooth restoration is not even attempted by some.*

## CASE REPORT

A thirty-three year old male presented the desire to restore tooth number 8 **(Figures 1, 2)**. The patient was in excellent health and had no other periodontal or restorative needs. He was a regular patient in the practice and maintained impeccable hygiene. He had musculoskeletal signs but reported no symptoms. We discussed the musculoskeletal signs and symptoms form and did muscle palpations but his desire was to only restore tooth number 8. We discussed realistic expectations with color matching and he was willing to proceed even if we only made a 75% improvement. He and I were both comfortable with this expectation and mutually agreed to proceed knowing that conservatively, 75% was definitely in the realm of attainability.

With a full mouth series of radiographs, good study models

from PVS impressions, pre-operative photography including good facial shots and retracted views and a properly prepared patient (expectation – wise), the case was ready to be prepped.

Direct resin bonding and porcelain veneering were discussed with the patient. After weighing the pros and cons of both procedures, it was decided that placing a porcelain veneer would be the best choice for the most natural looking restoration.

Anesthetic was administered (1.8cc 2% lidocaine with 1:100,000 epinephrine x 1) and the tooth was prepped for an Empress porcelain veneer (**Figures 3, 4**). During the prep phase the decision to mask out the underlying darkness was made. It was decided that the lab would be able to pick out an appropriate ingot with the right amount of opacity to properly block out the color difference as compared to the adjacent teeth by using a stump shade. This is a difficult decision to make and the author will usually try to control the color chairside by composite resin blockout if there is any question as to whether the lab will have difficulty in blocking the color discrepancy out. In this case the lab was comfortable with controlling the color with the proper ingot (010) selection.

The final prep was fine tuned and a polyvinyl siloxane impression (Kerr Take 1) was taken. The tooth was cleansed with Consepsis (Ultradent), air dried and and a temporary was fabricated chairside by freehanding a microfill composite (Cosmodent Renamel shades A-1, light translucency and white opaque) temporary directly on the prepped tooth with no temporary cement (**Figure 5**). Color mapping was completed and communicated to the lab along with pictures of the shade tabs for lab communication. A blend of 110 (Chromascope-Ivoclar Vivadent) in the cervical three fourths and B-1(Vita) in the incisal one fourth with a slight blend of light translucency and a halo of white opaque (**Figures 6, 7**). The stump shade was an 8 on the chromascope.

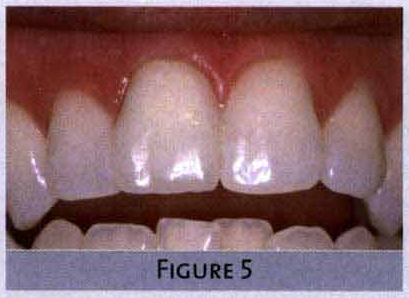
FIGURE 5

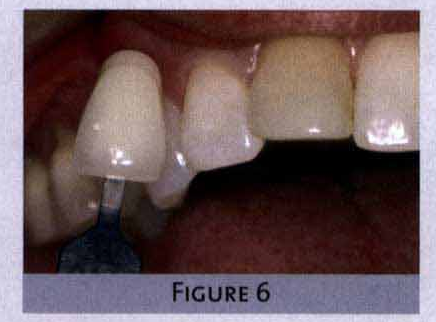
FIGURE 6

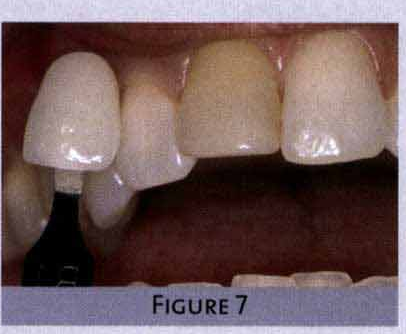
FIGURE 7

Three weeks after the prep appointment the patient returned for the placement of the final veneer. No staining or sensitivity was noted and the patient was eager to receive his final restoration. After anesthetic was administered (1.8 cc 2% lidocaine with 1:100,000 epinephrine x 1), the temporary was easily removed with a spoon excavator and the tooth was debrided with hydrogen peroxide, rinsed and ready for a dry try-in of the veneer for marginal fit, interproximal contacts, shape, size and contour. Upon my approval the veneer was filled with a light yellow try-in paste (VariolinkII). The hue, chroma, value and translucency matched the adjacent teeth very closely. Upon the TEAM's and patient's approval the veneer was removed and rinsed with copious water spray and air dried. The veneer was then acid etched (Ultradent) with 37% phosphoric acid, rinsed with copious water spray and air dried. The internal aspect of the veneer was then coated with Kerr's Silane Primer and allowed to air dry.

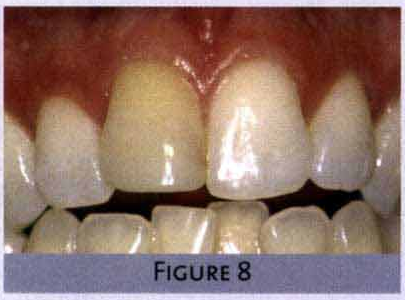
FIGURE 8

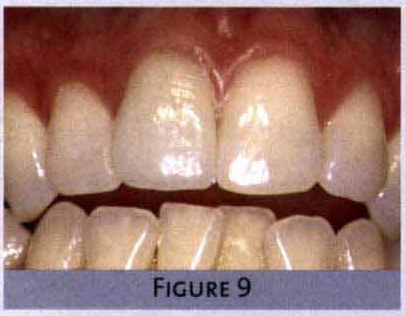

FIGURE 9

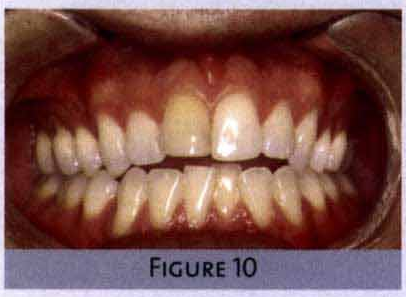

FIGURE 10

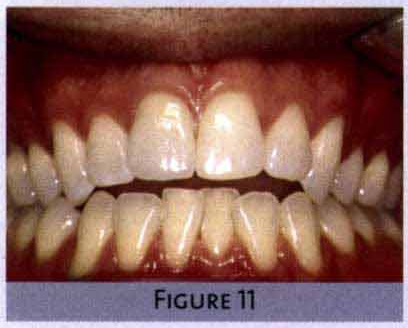

FIGURE 11

At this time a rubber dam was placed and the tooth was cleaned with Consepsis, rinsed with copious water spray and lightly dried. 37% phosphoric acid was then applied to the prepped tooth (first on the enamel for 15 seconds then 10 seconds on the dentin). After rinsing off the etchant, the prepped tooth was moistened with Tublicid Red (Global) and the excess was blotted off with a multi-brush. The tooth was then coated with two coats of Optibond Solo Plus (Kerr) and lightly air thinned. Care was taken to make sure there was no pooling of the primer on the margins and inter-proximally before it was light cured for 10 seconds (Optilux 501 Kerr). The veneer was then filled with the luting resin (VariolinkII light yellow) and placed on the prepped tooth and gently seated. Excess luting resin was cleaned off using a disposable brush and the veneer was ready to be spot tacked (3 seconds facially at the margin and 3 seconds lingually at the lingual margin) into place. At this time the veneer was firmly seated using finger pressure and the end of a disposable brush pressing incisal-cervically and facial-lingually simultaneously. This allows for proper seating of the veneer and eliminates the possibility of suck-back and potential leakage. Once spot tacked, the veneer was flossed mesially and distally and the final cure was performed (40 seconds on the facial, lingual and incisal). Final clean up was carried out by removing any gross excess with a scaler then an enhance cup was used lightly for final marginal clean up. The occlusion was checked and the final polish was completed using porcelain polishing points and cups (Brasseler - Dialite) and porcelain polishing paste. Immediately after the rubber dam was removed, the final inspection by everyone involved revealed a successful final restoration that fulfilled the wishes of my patient for at least a 75% or better color match (**Figure 8, 9**). A two year follow up comparing the pre-op condition (**Figure 10**), to the final (**Figure 11**), revealed an excellent match and great color stability.

## CONCLUSION

Attempting to restore a single tooth with an aesthetic restoration requires careful planning, great communication with your lab via color mapping and photography, a good understanding of color and bonding protocol and an honest and realistic conveyance to your patient of what can be accomplished clinically. When all of these details are taken into consideration a very predictable and rewarding result can be achieved when restoring a single anterior tooth. Even though this restoration can be one of the most challenging in dentistry, it can also be one of the most rewarding for both you and your patient.

A special thanks to my lab technician for making my life easier by making this beautiful lifelike restoration, and more importantly really caring about getting it done right the first time.

> ***Even though this restoration can be one of the most challenging in dentistry, it can also be one of the most rewarding for both you and your patient.***

*Dr. Timothy C. Adams is a Clinical Director at LVI. He is a graduate of Indiana University School of Dentistry where he taught clinical dentistry for 5 years. He maintained a highly successful full-time private practice emphasizing aesthetic-restorative dentistry for 17 years. He followed his dream of teaching and moved to Las Vegas to join the full-time LVI faculty. An enthusiastic lecturer, instructor and author of many articles on the latest aesthetic-restorative procedures, Tim is part of the LVI Faculty practice.*